بسم الله الرحمن الرحیم



# Autoimmune bile duct disease

Ali bahari,Gastroenterologist

Mashhad University of Medical Sciences

Emam REZA Hospital

1402/7/27

# Autoimmune bile duct disease

## Classification, Dx

- Primary biliary cholangitis
- Autoimmune Hepatitis-Primary biliary cholangitis OVERLAPS
- Primary Sclerosing Cholangitis
- Autoimmune Hepatitis- Primary Sclerosing Cholangitis OVERLAPS
- IgG4-associated cholangitis

# Primary biliary cholangitis

- Diagnostic criteria
  - no extrahepatic biliary obstruction
  - no comorbidity affecting the liver
  - at least two of the following are present :
    - ALP at least 1.5 times the upper limit of normal
    - Presence of AMA at a titre of 1:40 or higher
    - Histologic evidence of PBC (nonsuppurative destructive cholangitis and destruction of interlobular bile ducts)
      - liver biopsy is often not required to make the diagnosis

# Primary biliary cholangitis

**RECOMMENDATION 1**

We recommend that any patient with persistently elevated cholestatic liver biochemistry (raised ALP or GGT) without an alternative cause should have autoantibodies checked for anti-mitochondrial (AMA) and anti-nuclear (ANA) reactivity. (Strong; High)

Hirschfield GM, et al. Gut 2018;67

# Primary biliary cholangitis

**RECOMMENDATION 2**

We recommend that the presence of AMA (>1 in 40) or highly PBC-specific ANA, in the appropriate context of cholestatic liver biochemistry, without alternative explanation, is usually sufficient for confidently reaching the diagnosis of PBC. (Strong; High)

Hirschfield GM, et al. Gut 2018;67

# Primary biliary cholangitis

**RECOMMENDATION 4**

We recommend all patients with suspected PBC should have a baseline abdominal ultrasound as part of their assessment. (Strong; High)

Hirschfield GM, et al. Gut 2018;67

# Primary biliary cholangitis

**RECOMMENDATION 5**

We recommend liver biopsy is not usually required in the diagnosis of PBC or for monitoring of disease progression (Strong; High

Hirschfield GM, et al. Gut 2018;67

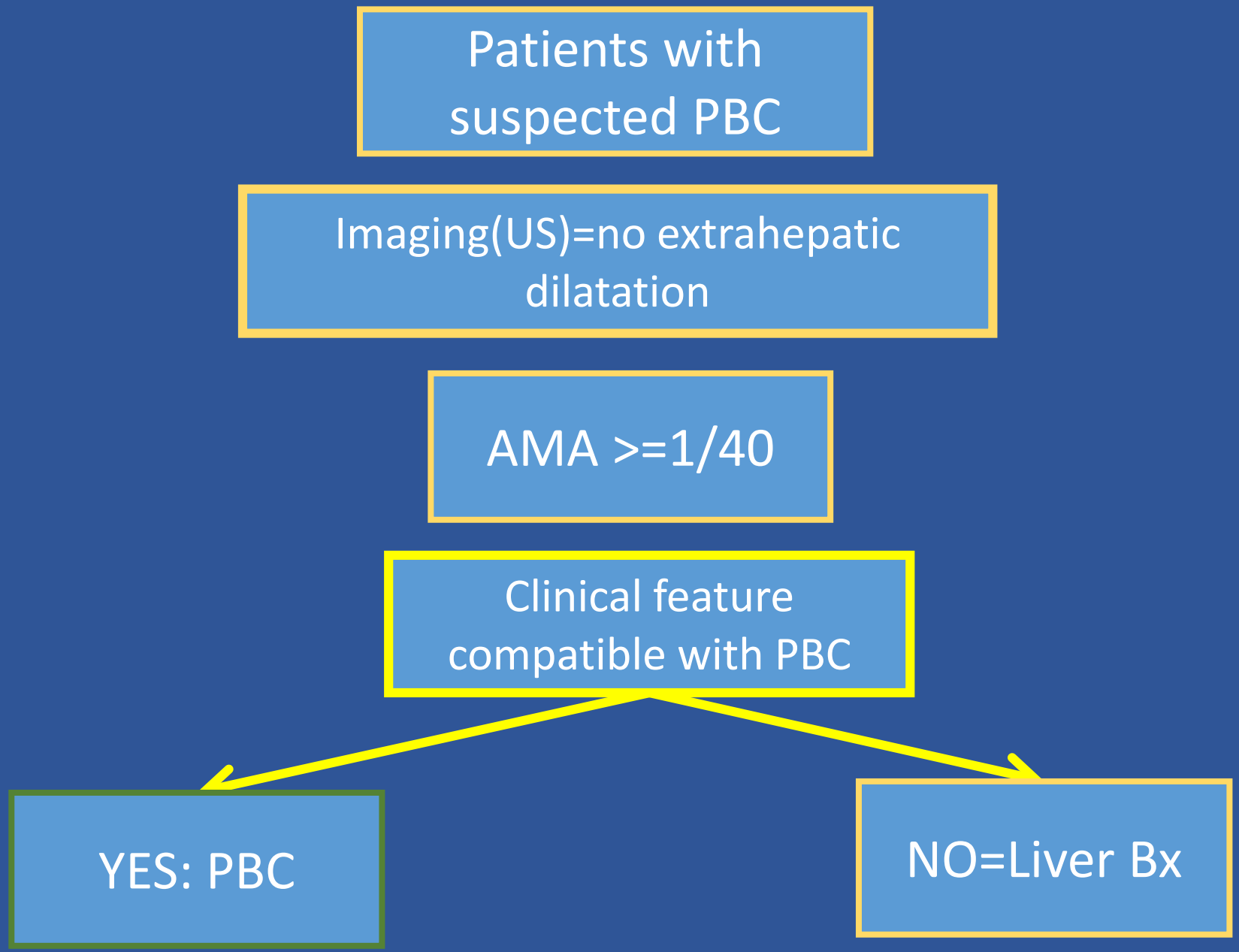
Patients with suspected PBC
Imaging(US)=no extrahepatic dilatation
AMA >=1/40
Clinical feature compatible with PBC
YES: PBC
NO=Liver Bx

# Primary biliary cholangitis

**RECOMMENDATION 7**

We recommend that, in the presence of cholestatic serum liver tests but an absence of diagnostic autoantibodies, the confirmation of PBC requires a liver biopsy. (Strong; Moderate)

Hirschfield GM, et al. Gut 2018;67

# Primary biliary cholangitis

**RECOMMENDATION 8**

We recommend that liver biopsy can be considered if there is a clinical suspicion of co-existing disease (eg, additional injury from non-alcoholic fatty liver disease (NAFLD), viral hepatitis or alcohol use) or the presence of overlapping autoimmune hepatitis, either at diagnosis or during follow-up. (Strong; Moderate)

Hirschfield GM, et al. Gut 2018;67

# Liver biopsy

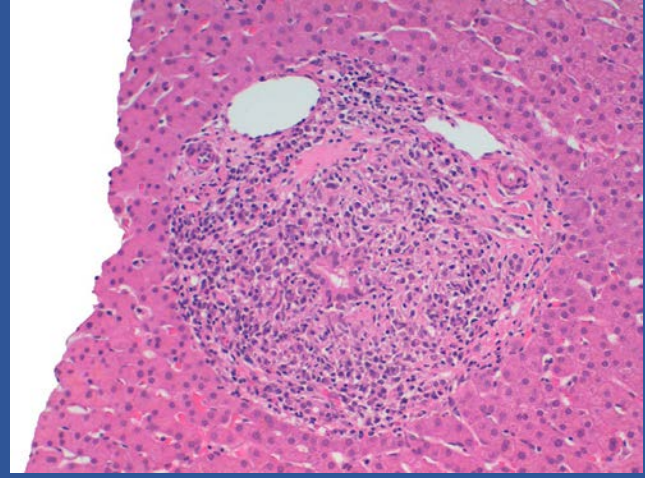

- During the diagnosis of primary biliary cholangitis
  - testing for specific autoantibodies (AMA M2, anti-gp210 or anti-sp100) is negative
  - a hepatic comorbidity that may influence the management (overlap syndrome, NAFLD) is suspected
  - the stage of the disease cannot be reliably assessed by liver stiffness measurement
- During the follow-up of primary biliary cholangitis
  - insufficient biochemical response, especially to rule out an overlap syndrome
  - disease progression suggested by liver stiffness measurement

# Primary biliary cholangitis

- **Risk assessment**
  - Serum liver test
    - Bil,Alb,INR,Plt,ALT,AST,ALP
  - Imaging
    - US
  - Elastography
  - Age<45 yr
  - Male

Contents lists available at ScienceDirect

Annals of Hepatology

journal homepage: www.elsevier.es/annalsofhepatology



Original article

# Systematic review and meta-analysis: Transient elastography compared to liver biopsy for staging of liver fibrosis in primary biliary cholangitis

- 4 studies , 377 patients

| | F3 | F4 |
|---|---|---|
| Pooled sensitivity | 68% | 90% |
| Pooled specificity | 92% | 94% |

*Conclusions:* TE performance compared with liver biopsy in adult patients with PBC was excellent for staging liver fibrosis and was able to rule out cirrhosis in clinical practice.

# Accuracy of Transient Elastography in Assessing Fibrosis at Diagnosis in Naïve Patients With Primary Biliary Cholangitis: A Dual Cut-Off Approach

- 167 treatment-naïve PBC patients who underwent liver biopsy at diagnosis at 6 Italian centers.
- VCTE examinations were completed within 12 weeks of LB.
- LSM cutoffs ≤6.5 and >11.0 kPa enabled to exclude and confirm, respectively, advanced fibrosis AF
  - (NPV = 0.94; PPV = 0.89).
- Multivariable analysis found that the only parameter affecting LSM was fibrosis stage.

*Hepatology, Vol. 74, No. 3, 2021*

# Primary biliary cholangitis

**RECOMMENDATION 9**

We suggest that at baseline it is reasonable to screen all patients with PBC for celiac, thyroid disease and Sjögren's syndrome.

Hirschfield GM, et al. Gut 2018;67

# Primary biliary cholangitis

- ↑ALP, AMA(+), clinical picture suggestive of PBC:



# Primary biliary cholangitis

- ↑ ALP, AMA(+), clinical picture inconsistent with PBC (overweight, diabetes, or systemic disease)



# Primary biliary cholangitis

↑ALP, AMA(-)



# Primary biliary cholangitis

- Normal ALP, AMA(+) , suspicion for PBC

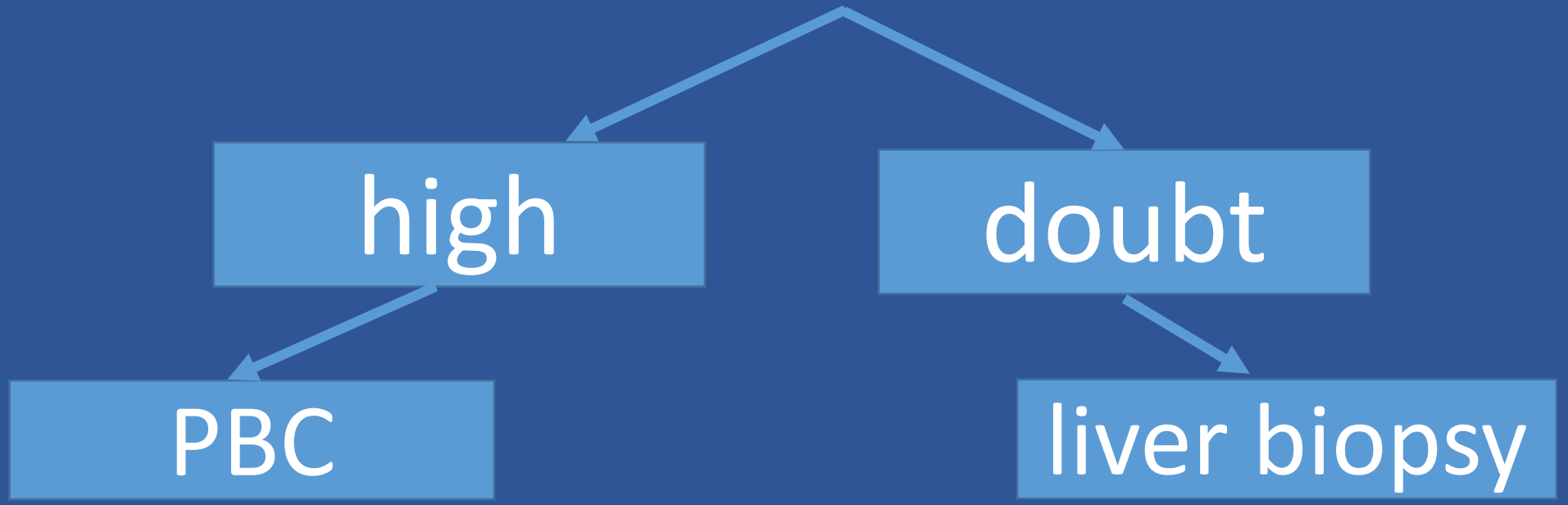

# Primary biliary cholangitis

Normal ALP , AMA(-)

Diagnosis of PBC is excluded

# AUTOIMMUNE HEPATITIS-PBC OVERLAPS

- 1-Histologic features of AIH ***AND*** AMA(+)
  - AMA-positive autoimmune hepatitis
- 2-Histologic features suggesting PBC ***AND*** seronegative for AMA and generally have ANA(+) and/or ASMA(+)
  - immune cholangiopathy, autoimmune cholangiopathy, immune cholangitis, and autoimmune cholangitis
  - AMA-negative PBC

# Primary Sclerosing Cholangitis

- **Classic PSC**
  - The biliary strictures in patients with PSC may be focal, with normal intervening areas, or diffuse, involving long segments.
- **Small duct PSC(**pericholangitis)
  - Cholangiography is normal

**Algorithm of diagnostic measures in chronic cholestasis**

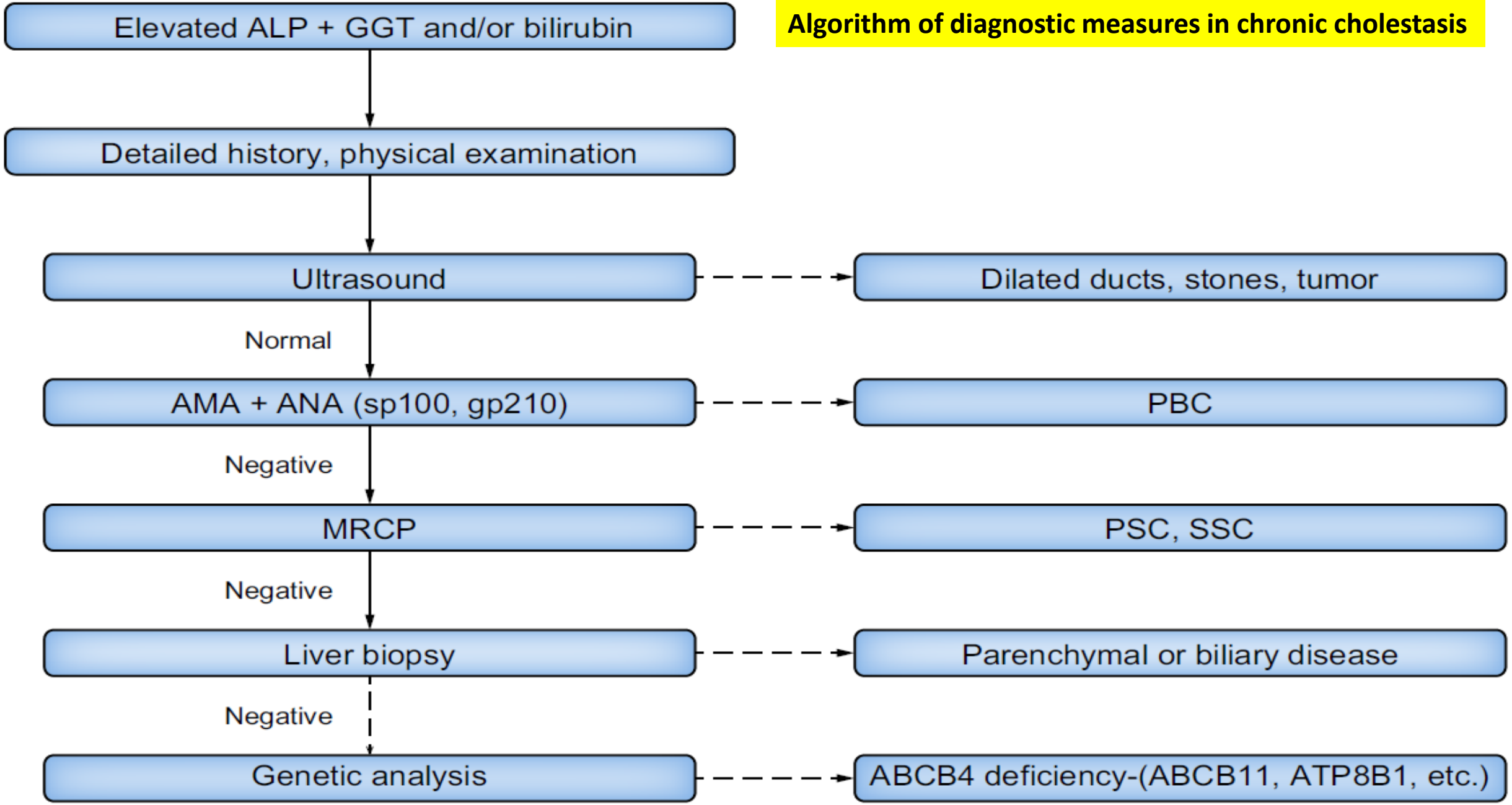

# Primary Sclerosing Cholangitis

- In adult patients presenting with elevated serum markers of cholestasis, a diagnosis of large duct PSC should be made in the presence of typical findings of sclerosing cholangitis on high-quality cholangiography and after exclusion of secondary causes. The preferred diagnostic test is magnetic resonance cholangiopancreaticography (MRCP) **(LoE 2, strong recommendation, 93% consensus).**

*Journal of Hepatology 2022 vol. 77*

# Secondary sclerosing cholangitis

- Chronic bacterial cholangitis
- Infectious or ischemic cholangiopathy
- Cholangiocarcinoma
- Choledocholithiasis
- Diffuse intrahepatic metastases
- Intra-arterial chemotherapy
- Portal hypertensive biliopathy
- Recurrent pancreatitis
- Recurrent pyogenic cholangitis
- Surgical biliary trauma

# Primary Sclerosing Cholangitis

- A diagnosis of small duct PSC should be considered in patients with elevated serum markers of cholestasis of unknown cause, normal high-quality cholangiography, and compatible histology of PSC, particularly in those with concomitant inflammatory bowel disease (IBD) **(LoE 3, strong recommendation, 88% consensus).**

*Journal of Hepatology 2022 vol. 77*

# Primary Sclerosing Cholangitis

- Autoantibodies should not be used to diagnose or risk-stratify people with PSC (**LoE 4, strong recommendation, 100% consensus**).

*Journal of Hepatology 2022 vol. 77*

# Primary Sclerosing Cholangitis

- A liver biopsy should be performed in adults suspected of having PSC whose high-quality MRCP is normal, to confirm or exclude small duct PSC (**LoE 4, strong recommendation, 88% consensus**).

- A liver biopsy should be considered in people with PSC and co-existing features of AIH including markedly elevated transaminases, high IgG levels, and positive autoantibodies compatible with AIH (**LoE 4, strong recommendation, 92% consensus**).

*Journal of Hepatology 2022 vol. 77*

# Primary Sclerosing Cholangitis

- Determination of serum IgG4 is suggested in every adult patient with large duct sclerosing cholangitis at the time of diagnosis **(LoE 3, weak recommendation, 91% consensus).**

*Journal of Hepatology 2022 vol. 77*

# Primary Sclerosing Cholangitis

- **Risk assessment**
  - Serum liver test :every 6-12 month
    - Bil,Alb,INR, Plt,ALT,AST,ALP
  - Imaging
    - US
    - MRI+MRCP
  - T. Elastography : every 2-3 yr
  - Serum fibrosis test:  every 2-3 yr

# Primary Sclerosing Cholangitis

- Ileocolonoscopy with biopsies from all colonic segments including the terminal ileum, regardless of the presence of lesions, is recommended at the time of PSC diagnosis **(LoE 3, strong recommendation, 100% consensus).**

- A diagnostic colonoscopy can be considered every 5 years in people with PSC where no IBD is present or whenever complaints suspicious for IBD occur **(LoE 5, weak recommendation, 92% consensus).**

*Journal of Hepatology 2022 vol. 77*

# AUTOIMMUNE HEPATITIS-PSC OVERLAPS

- Clinical, biochemical, and histologic findings of AIH but have cholangiographic abnormalities characteristic of PSC

# AUTOIMMUNE HEPATITIS-PSC OVERLAPS

- Patients who have clinical and serologic features of AIH and
  - Pruritus
  - Ulcerative colitis
  - Bile duct abnormalities on histology
  - Cholestatic laboratory changes (ALP> 2 upper limit of normal)
  - No response to corticosteroid therapy
  - An abnormal cholangiogram
- Patients diagnosed with PSC who have
  - high levels of IgG, circulating ANA,ASMA(titer >1:40), and moderate to severe interface hepatitis on liver biopsy

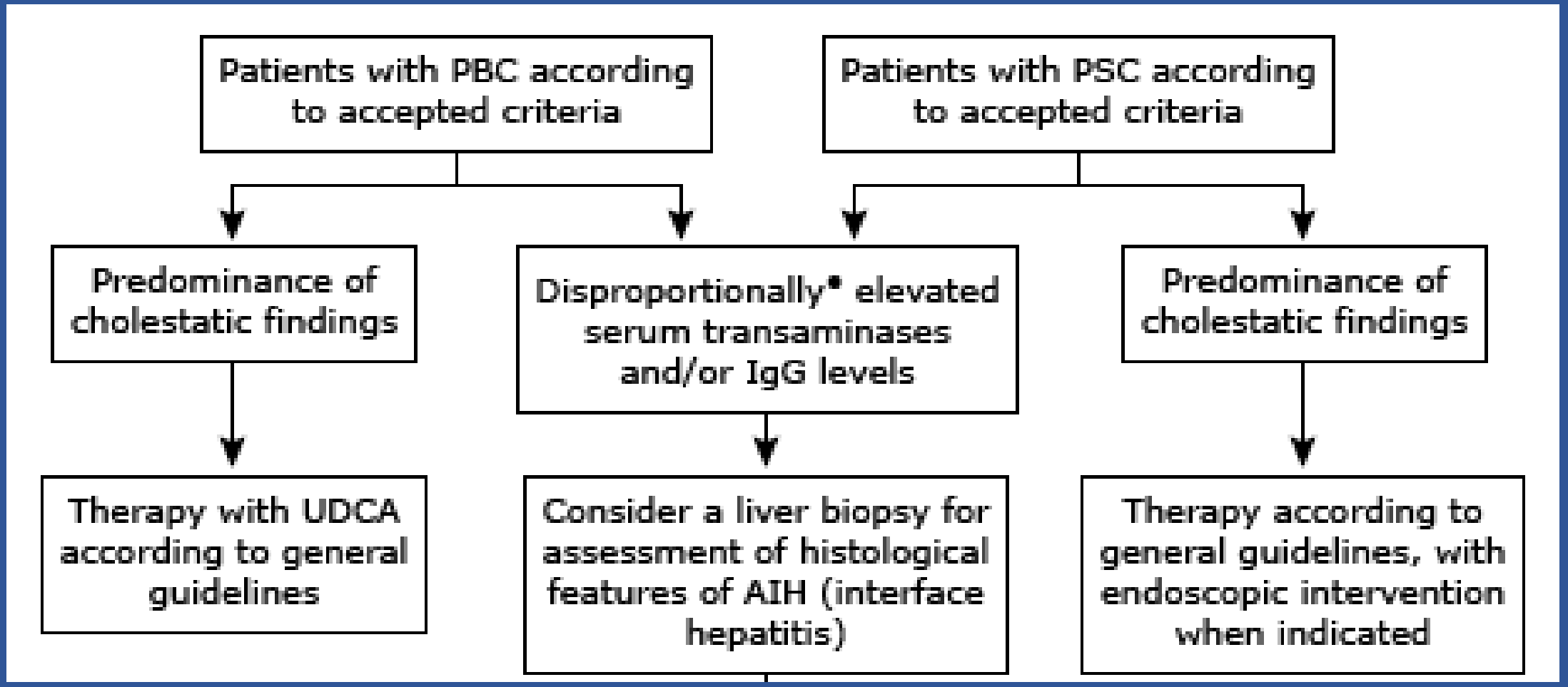
Patients with PBC according to accepted criteria
Patients with PSC according to accepted criteria
Predominance of cholestatic findings
Disproportionally* elevated serum transaminases and/or IgG levels
Predominance of cholestatic findings
Therapy with UDCA according to general guidelines
Consider a liver biopsy for assessment of histological features of AIH (interface hepatitis)
Therapy according to general guidelines, with endoscopic intervention when indicated

# IgG4-associated cholangitis

- A form of glucocorticoid-responsive sclerosing cholangitis that shares clinical and radiographic features with PSC may occur as part of the immunoglobulin G4 (IgG4)-related diseases.
- IgG4-associated cholangitis is the most frequent extrapancreatic manifestation of type 1 autoimmune pancreatitis (IgG4-related), present in over 70 percent of such patients
- It also rarely occurs in the absence of pancreatitis.
- Serum IgG4 should be measured in all newly diagnosed patients with PSC

# IgG4-associated cholangitis

**Recommendation 1:** We recommend that elevated serum IgG4 levels support the diagnosis of clinically suspected IgG4-RD but cannot be relied on for making a definite diagnosis, or distinguishing IgG4-SC from PSC (*strength of recommendation: STRONG; quality of evidence: MODERATE*).

*Chapman MH, et al. Gut 2019;**68**:*

# IgG4-associated cholangitis

**Recommendation 2:** We recommend that in patients with suspected IgG4-SC, attempts should be made to obtain a confirmatory histological diagnosis (*strength of recommendation: STRONG; quality of evidence: MODERATE*).

*Chapman MH, et al. Gut 2019;**68**:*

**Table 2** Clinical parameters in differentiating IgG4-related sclerosing cholangitis (IgG4-SC) from primary sclerosing cholangitis (PSC)

| Clinical feature supportive of IgG4-SC or PSC | PSC | IgG4-SC |
|---|---|---|
| Male sex | + | ++ |
| Younger age | ++ | + |
| Pancreatic mass or enlargement on CT | – | ++ |
| Pancreatic ductal abnormalities | +/- | +++ |
| Raised serum IgG4 | +/- | ++ |
| Ampullary biopsy with >10 IgG4 plasma cells per high power field | – | +++ |
| Liver/tissue biopsy with >10 IgG4 plasma cells per high power field | +/– | +++ |
| Pancreatic exocrine insufficiency | – | ++ |
| Other associated systemic fibrosclerotic disease | – | ++ |
| Cholangiographic changes | ++ | ++ |
| Presence of inflammatory bowel disease | ++ | +/– |
| Improvement with steroid treatment | +/– | +++ |

# Registry of autoimmune liver diseases in Iran in three years

- 4,491 patients with autoimmune liver diseases
- 70 % were female.
- Mean age of the patients was 43.5 years
  - 2,525 (56.2%) autoimmune hepatitis cases (61.6% female)
  - 836 (18.6%) PSC cases (63% female)
  - 557 (12.4%) PBC cases (14.7% female)
  - 540 (12%) variant (overlap) syndrome (12.4% female)
  - 18 (0.4%) autoimmune cholangiopathy
  - 3 (0.1%) IgG-4 related cholangiography

# Case 1

- A 47-year-old woman presented with chronic fatigue and abnormal liver function tests for the previous 6 months
- Physical exam: unremarkable
- Lab data:
  - ALP  870 mg/dl (normal range <300)
  - ALT  70 mg/dl (normal <30)
  - bilirubin  1.1 mg/dl
  - ANA  1:160
  - AMA 1:80 (M2 subunit positive).
- Liver ultrasound : normal

*What is the most likely diagnosis?*

- a. Cholestatic drug reaction.
- b. Primary biliary cholangitis.
- c. Primary biliary cholangitis – autoimmune hepatitis overlap syndrome.
- d. Primary sclerosing cholangitis.

*Do you recommend MRCP/Liver Bx/Both?*

# Case 2

- A 46-year-old woman presents to the clinic with a one-year history of progressive fatigue and pruritus.
- She has a two-year history of an elevated alkaline phosphatase.
- PMH: well-controlled hypothyroidism and hyperlipidemia.
- Medications: levothyroxine and simvastatin.
- Physical exam reveals scattered excoriations on her extremities and chest.

# Case 2

- Lab data:
  - Total bilirubin 1.8 mg/dL  Direct bilirubin 0.9 mg/dL
  - ALP 1200 mg/dl  ALT 100 mg/dl  Albumin 4.5 g/dL  INR 1.0
  - IgA tissue transglutaminase = Neg
  - IgG4= 12.0 mg/dL
  - ANA= 1:128  ASMA =Negative  AMA= Negative
  - HIV Negative
  - Serum protein electrophoresis =Normal
- US=NL

*Do you recommend MRCP/Liver Bx/Both?*

# Case 3

- A 40-year-old man presents with painless jaundice, without fever,weight loss or anorexia.
- Lab data:
  - ALP:  1200 mg/dl
  - total bilirubin : 8.4 mg/dL ,  direct bilirubin of 4.7 mg /dL.
- US= IHDs dilatation
- MRCP+MRI: stricture of the proximal CHD with upstream biliary dilation AND retroperitoneal fibrosis.
- ERCP is performed and brush cytology of the bile duct stricture is non-diagnostic despite three separate attempts.

# *What is the most appropriate diagnostic test?*

- A- IgG4
- B-CA19-9
- C-FISH
- D-EUS+FNB



